

CASE SUMMARY

Canine, "Fluff", Mass Evaluation



Case Courtesy of:

Dr. Michael Petty, Animal Pain Center Arbor Pointe Veterinary Hospital, Canton, MI

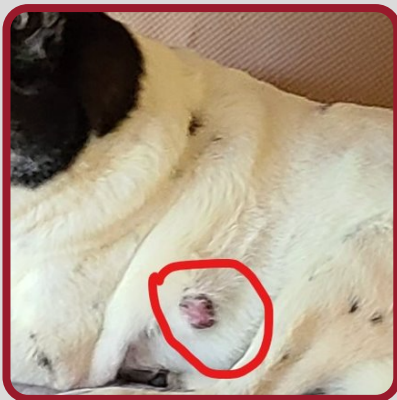Signalment: Canine, 13yo F, Canaan, "Fluff"

History: Fluff presented for a mass that was steadily growing over a few months. Previously, she had a mast cell tumor surgically removed that dehisced and she had a long and expensive recovery period.

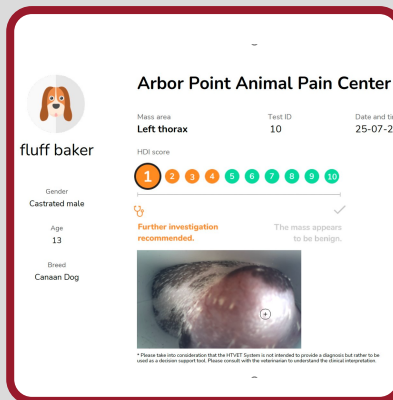
Exam Findings: A cutaneous mass on the left lateral thorax was present.

Diagnostics: The mass was scanned with HT Vista because the owner wanted to avoid surgery. It received a score of 1 (further investigation recommended), therefore surgery was pursued. Histopathology confirmed the mass was a soft tissue sarcoma, grade 1.

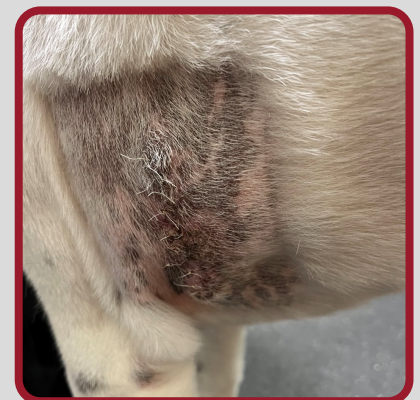
Comments: The HT Vista result gave the owner confidence in moving forward with surgery, especially since the patient previously had a poor surgical recovery.



Cutaneous mass of the left lateral thorax



HT Vista result for mass on left thorax



Post-op surgical site