

CASE SUMMARY

Canine, "Remington", Mass Evaluation



Case Courtesy of:

Dr. Michael Petty, Animal Pain Center Arbor Pointe Veterinary Hospital, Canton, MI

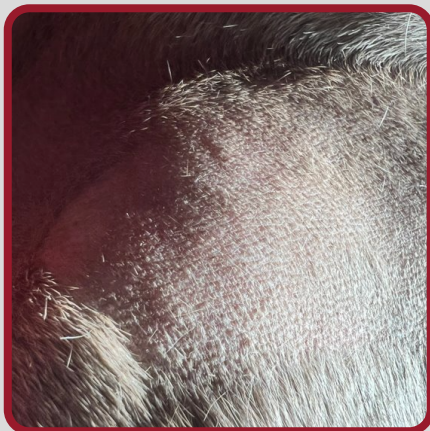
Signalment: Canine, 6yo MN, Weimaraner, "Remington"

History: Remington presented for a laceration but during the exam, it was requested that an enlarging mass be evaluated.

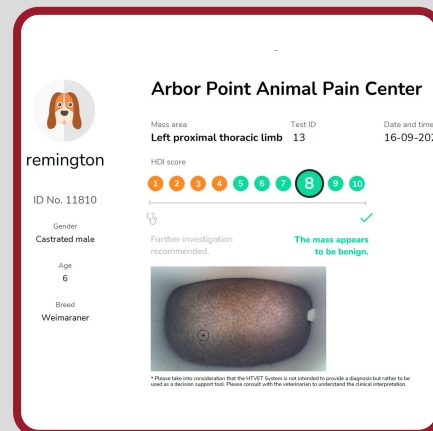
Exam Findings: A soft, fluctuant mass was present on the left antebrachium.

Diagnostics: The mass was scanned with HT Vista and received a score of 8 (the mass appears benign). Cytology was also performed and adipose cells were seen.

Comments: The location of this mass would have made taking adequate surgical margins difficult. Though this patient was undergoing a laceration repair, using HT Vista to confirm the mass was benign allowed an extensive and costly surgery to be avoided. The owner was relieved to have confirmation the mass was benign since surgical removal was not practical.



HT Vista scan area



HT Vista results